



PATIENT

Bubu Gonzalez

SPECIES

Canine

BREED

Pug

SEX

MN

AGE

9 y

WEIGHT

27.6 lb

INTERPRETED BY

Keith Blass, DVM, MS,
DACVIM (Cardiology)

IMAGING PERFORMED BY

Gabriel Ferrer, DVM

HOSPITAL NAME

Pulse Pet Ultrasound
Services

REFERRING VET

Dr. Fernandez

INVOICE

DATE

3/20/26

PRESENTING CLINICAL SIGNS

Presented for abdominal distension, exercise intolerance, lethargy, and increased respiratory effort. Radiographs showed cardiomegaly.

ECHOCARDIOGRAPHIC FINDINGS

2D, M-mode, and Doppler study.

A mild to moderate volume of pericardial effusion is present. Left atrial size is normal. The mitral valve appears normal, though trace mitral regurgitation is present. Left ventricular dimensions are normal. Left ventricular systolic function is normal. The aorta and aortic valve appear normal, though trace aortic insufficiency is present. Right atrial and right ventricular dimensions are normal. There is mild diastolic collapse of the right atrial free wall. The tricuspid valve appears normal, though trace tricuspid regurgitation is present. The pulmonary artery and pulmonic valve are normal. No cardiac masses are seen. Mild peritoneal effusion is visible.

ECG during echo: Sinus rhythm

LA - 25.4 mm
LVIDd - 22.8 mm
LVIDs - 14.0 mm
FS - 38.6%
RA - 20.8 mm
LVOT - 2.29 m/s
RVOT - 1.43 m/s

ASSESSMENT/RECOMMENDATIONS

This examination demonstrates a mild to moderate volume of pericardial effusion. There is mild diastolic collapse of Bubu's right atrial free wall, suggesting that his effusion is resulting in some degree of cardiac tamponade. If tamponade is indeed present, it could explain Bubu's presenting clinical signs, as well as his peritoneal effusion formation.

No reason for Bubu's pericardial effusion is appreciated in the image set. The two most common causes of pericardial effusion in dogs, accounting for almost all cases, include cardiac neoplasia and idiopathic effusion, while other causes, such as infectious effusion, being very rare. While no evidence of neoplasia is appreciated in this exam, its presence cannot be ruled out, as echocardiogram is only ~70% sensitive at detecting cardiac masses.

Pericardiocentesis is recommended to relieve Bubu's tamponade, as well as to submit samples of effusion for analysis/cytology +/- culture. If the procedure is not performed, Bubu's clinical signs and peritoneal effusion should persist, and, it's possible that the tamponade could be fatal. Once the tamponade is relieved, Bubu's peritoneal effusion should start to resolve on its own.

Consideration can be given to cardiac CT to further evaluate for the presence of neoplasia. If not possible, a recheck echocardiogram is recommended in 4 months, sooner if clinical signs compatible with tamponade recur.



PATIENT

Bubu Gonzalez

SPECIES

Canine

BREED

Pug

SEX

MN

AGE

9 y

WEIGHT

27.6 lb

INTERPRETED BY

Keith Blass, DVM, MS,
DACVIM (Cardiology)

IMAGING PERFORMED BY

Gabriel Ferrer, DVM

HOSPITAL NAME

Pulse Pet Ultrasound
Services

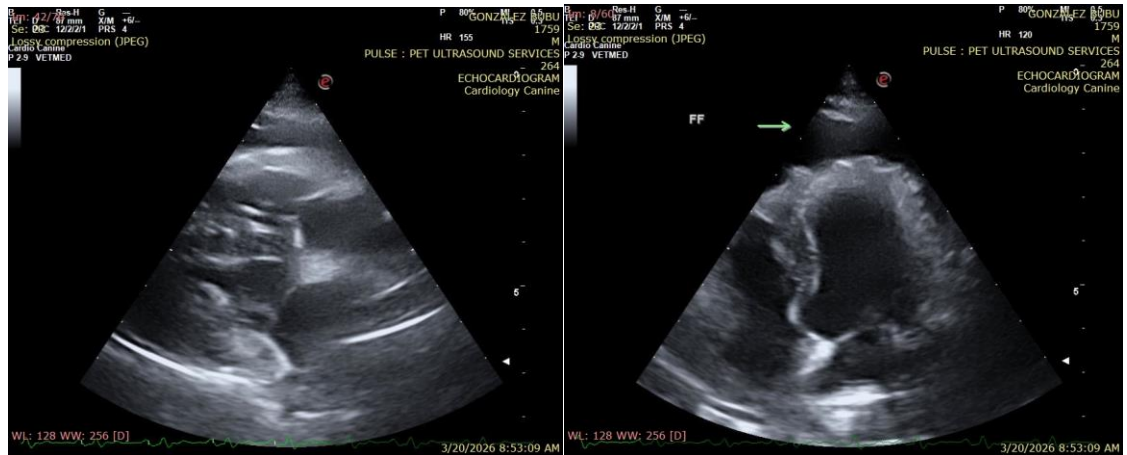
REFERRING VET

Dr. Fernandez

INVOICE

DATE

3/20/26



The information and recommendations provided are based on the images presented by the referring veterinarian/sonographer. No evaluation can be communicated regarding pathology that was not visible in the image/video clips provided.

Thank you for this referral. If the clinical or image interpretation does not parallel your findings or if I can be of any further assistance please contact me.

Keith Blass, DVM, MS, DACVIM (Cardiology) info@SonoPath.com